

Hip Dysplasia

Definition: malformation of the hip joint

- this malformation lead to laxity within the joint
 - laxity is the degree of mobility of the femoral head in the acetabulum and joint capsule
- can lead to degenerative joint disease (arthritis), restricted joint mobility, pain and lameness
- particularly common in large breeds such as Saint Bernards, Alaskan Malamutes, bulldogs, Boxers, Collies, Dobermans, Rottweilers, Labrador Retrievers, Old English Sheepdogs, pointers and Standard Poodles
- smaller breeds are not spared but often they have less stress on their joints therefore no obvious symptoms

Genetics

- hip dysplasia is a polygenic disorder which means it is controlled by more than one gene
- simple inheritance therefore does not apply to hip dysplasia
- because there are multiple genes responsible for the development of hip dysplasia, there are also different combinations of these genes that lead to development of hip dysplasia
- one of the reasons that it is difficult to breed hip dysplasia out of breeds is that breeders often are only selecting for depth of pedigree (parents and grandparents) and not breadth of pedigree (siblings)
- the appearance of normal hips in the parents does not reflect the genes that they are carrying
 - for example:
 - one study showed that when two normal dogs were bred they produced 19-36% dysplastic offspring and when two dysplastic dogs were bred the produced 63-93% dysplastic dogs
- siblings must also be considered in breeding programs
 - for example individual dogs with normal hips from litters with high incidence of hip dysplasia are more likely to carry a higher combination of affected genes and therefore produce more affected offspring
- in addition to hip dysplasia being a polygenic disorder, there is also lack of an early marker therefore the disorder is difficult to control

Diagnosis:

- palpation of the hip joint in puppies with hip dysplasia may reveal a click or pop
- there are several methods described to palpate puppies hips, but none can be considered diagnostic
- diagnosis is made when radiographs are taken with the hips extended and the dog lying on its back
- the best quality radiographs are made when the dog is anesthetized to allow full extension of the hip joint

-it is important to note that radiographic evidence of hip dysplasia does not mean that a dog will be clinical for hip dysplasia

Screening Methods

- two screening methods for dogs used in breeding programs
 - OFA is a subjective analysis of the hip extended view by a board certified veterinary radiologist
 - OFA is a not-for-profit foundation that was established in 1966
 - dog must be 24 months of age or older to be OFA certified
 - grading is excellent, good, fair, borderline or dysplastic
 - PennHip is a method that actually measures the laxity present in the hip joint
 - developed by Gail Smith and other veterinarians at University of Pennsylvania School of Veterinary Medicine
 - reported to be accurate in dogs as young as 16 weeks
 - three radiographs are taken: the standard hip extended view and two others with the hips and stifles flexed in a near standing position all with the dog on its back
 - One is taken with the femoral heads forced deeply into the acetabulum and the other with the distracting device forcing the femoral heads as far away as possible from the acetabulum to maximize laxity
 - dogs are given a number, distraction index, that actually reflects the degree of laxity within their hips
 - the database is breed specific to allow breeders to see where their dog falls within the rest of the breed evaluated using PennHip
 - as the distraction index increases, so does the risk for developing degenerative joint disease
 - it is recommended that only those dogs with a distraction index less than the average for the breed be used in a breeding program

Clinical Signs

- young dogs with hip dysplasia often have a very abnormal gait
 - the laxity leads to a very wobbly gait
 - they may also “bunny-hop” or place both hind limbs down at the same time while running
 - this ensures that one hip is never receiving the entire weight of the dog at one time
- young dogs may also be presented for pain associated with exercise
- as dogs with hip dysplasia age and degenerative joint disease develops, they are most often presented for lameness, difficulty rising from a sit or down position or crying out in pain
- it is important to note that not all dogs with hip dysplasia will develop clinical signs or severe degenerative joint disease
- it is estimated that about 75% of dogs with hip dysplasia at a young age never develop severe clinical signs

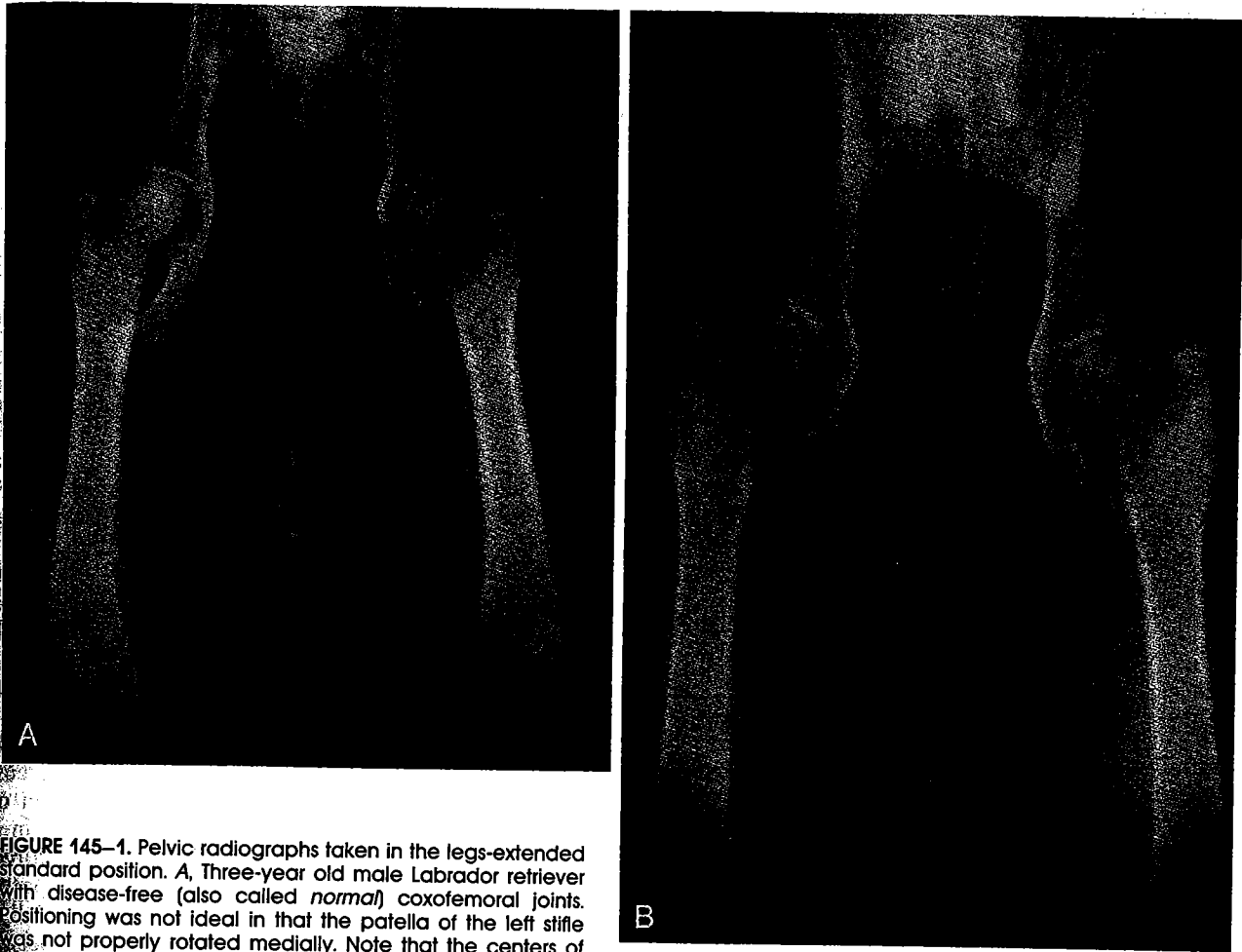
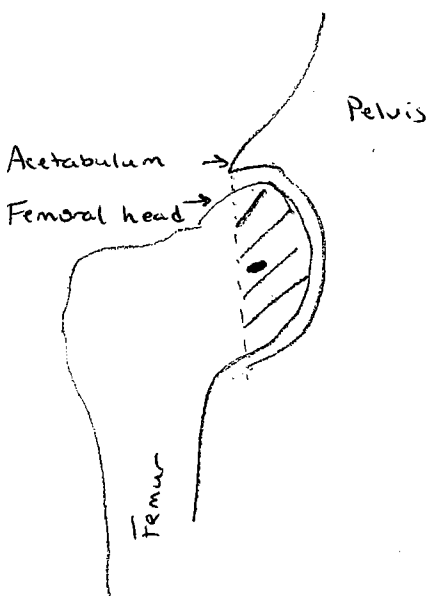


FIGURE 145-1. Pelvic radiographs taken in the legs-extended standard position. *A*, Three-year old male Labrador retriever with disease-free (also called *normal*) coxofemoral joints. Positioning was not ideal in that the patella of the left stifle was not properly rotated medially. Note that the centers of the femoral heads are medial to the cranial edge of the acetabula. *B*, Five-year old male Labrador retriever with advanced hip dysplasia. Note that the centers of the femoral heads are subluxated (partially displaced laterally); femoral heads and acetabula show proliferation (osteophytes) and remodeling.

Normal hip



Dysplastic Hip

